

MODERN CANINE DENTISTRY IN CANINE PRACTICE

A.K. Srivastava

Dean, MJF College of Veterinary & Animal Science, Chomu; Jaipur (Rajasthan), India

Canine dentistry is the branch of veterinary surgery, which deals with the study of canine dental diseases and their treatment. This also includes radiographic examination techniques, its effects on systemic diseases, prevention and treatment of periodontal diseases, endodontics, restorative dentistry, maxillofacial surgery and tooth extraction. (Holmstrom, 1998).

Canine dentistry is one of the fastest growing field of specialization and is gaining popularity not merely for esthetic purpose, but preventing condition like formation of plaque, tartar, gingivitis, gingival pocketing, infection to jaw bones and ultimately tooth loss.

Current status & importance

In 1908, Merillat Published Animal dentistry and diseases of the mouth, the first text completely devoted to the practice of veterinary and animal dentistry. In 1938, Garbutt described a variety of conditions of the teeth and the oral cavity and speculated the importance of a regular program of cleaning the teeth and dental prophylaxis in Veterinary practice. In 1986, the academy of veterinary dentistry was established in U.S.A to promote continuing education in dentistry.

Vasseur *et al.* (1981) reported that dental and oral surgical cases make up a significant portion of small animal practice. It has been estimated that about 85-90% of middle aged domestic dogs (4 yrs above) have some degree of periodontal disease due to lack of dental prophylaxis. Many digestive, cardiac and urogenital diseases have been proved to be secondary to diseases of teeth & gums. If teeth are not cleaned properly it leads to plaque formation, composed of food material and bacteria in between the teeth and over the tooth surface particularly near gum causing gingivitis at the margin. Progressions of disease lead to periodontitis and subsequently tooth loss.

Anatomical aspect

Teeth are classified into simple or complex types based on the interrelationship of dental anatomic structures including enamel, cementum, dentin and pulp. Simple or complex teeth are also known as brachydont (short

crown) and hypsodont (high crown) respectively.

All the teeth of the dog, cat, and human are simple or brachydont teeth (Court *et al.*, 1993). Harvey and Emily (1993) described four types of teeth in adult dogs i.e. Incisor- (I), Canine teeth - (C), Premolar- (P), Molar - (M). Tooth is divided into three parts i.e. (Crown, neck and root.) Supragingival crown is covered by enamel; where as subgingival root is covered by cementum. Enamel is the hardest substance in body being densely packed with hydroxyapatite (mineral) crystals and heavily mineralized with calcium salt. Cementum is a calcified connective tissue. Dentin a bone like material lies under the enamel and major component of the tooth. The root of the tooth is attached to the socket (alveolus) in the alveolar bone by periodontal ligament. Gingiva is the epithelial and connective tissue lining that surrounds and attach to the tooth and alveolar process. Gingival sulcus is the niche formed by the junction of the tooth and gingiva.

The canine tooth affected in descending order is carnassial tooth, maxillary canine, maxillary incisor, first three premolar and first molar.

Factors contribute to the development of poor oral hygiene

1. BREED - Toy breeds have the highest prevalence, mainly due to poor oral conformation and poor dietary habits (most of these little guys are hand-fed soft food from the table and are above chewing on a bone). Obligate mouth-breathers and heavy panting, as this reduces the protective nature of saliva. The incidences of periodontal disease are higher in smaller breed Pommeranian (40%), Mongrel (21%), Apso (16%) and like brachycephalic breeds having broad head and short jaw. While in larger breeds like German shepherd (5%), Labrador (4%), G. dane (3%), Doberman and Collies having long jaw lesser incidences has been recorded.

2. CONFORMATION – (i) Undershot and overshot jaws. (ii) Teeth overcrowding. (iii) Retained milk/temporary teeth.

3. DIET - Commercial biscuits generally shatter/crumble when chewed, resulting in an ineffective mechanical/abrasive clean. The

incidences of disease are more in dogs fed on vegetarian diet, readymade foods and home made soft diets in comparison to those dogs fed on non-vegetarian diet, hard and rough food material.

4. **REGULAR BRUSHING AND ATTENTION** – Lack of pet owner awareness lead to dental problems.

5. **AGE** - pathological changes are evident on average, from 3 years of age on and particularly prevalent in geriatrics.

6. **CONGENITAL/DEVELOPMENTAL** - Enamel hypoplasia.

7. **IMMUNO INCOMPETENCE** - Feline immunodeficiency virus.

8. **Sex**- The incidences of disease are more in male (57%) than female (36%). Selective preference of pet owner for male pet could be the probable reason.

9. **Oral Hygiene**- The dogs, which were given regular home dental care shows less incidence in comparison to those dogs, which were not looked after for oral hygiene.

10. **Habitat**- The incidences are more in pet dogs then stray dogs.

Common tooth problems

Dental calculus/ tartar: Dental calculus is composed of calcium salts, organic and inorganic material, bacteria, and serum exudates and food debris (Fig. 3).

Caries: Dental caries is chronic destruction of tooth substance caused by carbohydrate-fermenting bacteria.

Avulsion of tooth: Detachment of a tooth from alveolar bone without fracture of the tooth may occur due to trauma.

Cavities: True bacterial cavities are very rare in animal patients.

Dead teeth / Non vital teeth: There are many causes for tooth death in animals. The scary part is that these animals will almost never show outward signs of pain.

Carnasial Abscesses: This is an advanced form of an infected tooth. This condition is usually caused by a fractured tooth (usually the upper fourth premolar) that has been infected by the oral bacteria and died.

Broken (fractured) teeth: Broken (fractured) teeth are a very common occurrence in dogs. They can break due to trauma (hit by a car, ball, or rock) or due to chewing on hard objects. The most common teeth that are broken are the canine (fang) teeth and the upper

fourth premolar (large tooth on the top in the back) in dogs (Fig.1).

Enamel hypoplasia: Enamel hypoplasia is a condition where the enamel does not form correctly, or is damaged during its development. This will result in exposure of the underlying dentin.

Luxated teeth: Occasionally a tooth will be pulled out of its socket without fracturing the root. This is typically seen in canine teeth due to dogfights or other trauma. This can be partially (luxation or subluxation) or completely (avulsed) removed from the socket.

Various affection of teeth

1.Periodontal diseases, 2.Endodontal disease, 3.Orthodontic problems.

1. Periodontal diseases: The periodontal disease is an oral infection that results from the chronic retention of bacteria at the junction of tooth and the gingiva (Groove, 1982).The bacteria from the mouth accumulate on the surface of teeth are called plaque, which can eventually lead to tooth loss. The bacteria in the sub gingival plaque secrete toxins. These toxins damage the periodontal ligament, cementum, tooth attachment apparatus and alveolar bone of the socket (Fig.2). These diseases are classified as follows:

Stage - I (Mild or Gingivitis) - Simple gingivitis, swelling, redness and tender gums, pain, bleeding during examination, salivation with malodour (halitosis).

Stage - II (Moderate) - Loss of attachment up to 25% along with destructive periodontitis. Presence of purulent material, gingivitis is moderate, more painful, increased order of bleeding and halitosis, while plaque formation is little with absence of tartar. Intermittent anorexia is also observed.

Stage - III (Severe) - Loss of attachment between 25 to 50% profuse inflammation with relatively high plaque and little calculus. Higher degree of gingivitis, increased pain, excessive salivation with very much malodour and bleeding during examination while 100% plaque formation followed by dental tartar upto 50% or more and anorexia. Slight mobility is seen. Loosened gingival margins.

Stage - IV (Advance) - Loss of attachment greater than 50%. Infrabony pockets may be localized in a single area, complete calculus and mobility of teeth either of direction. It includes severe gingivitis, higher degree of

IMPORTANT PHOTOGRAPHS

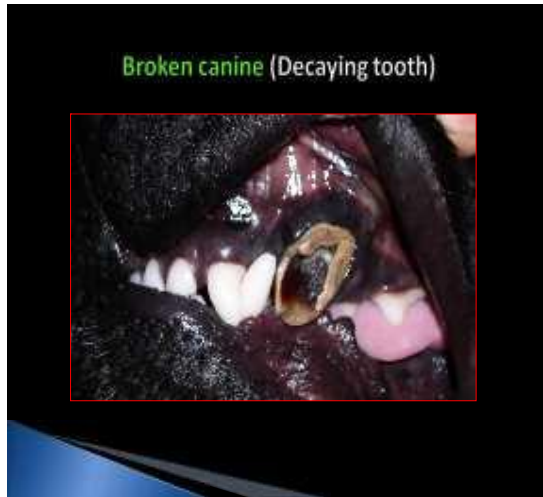


Fig. : 1

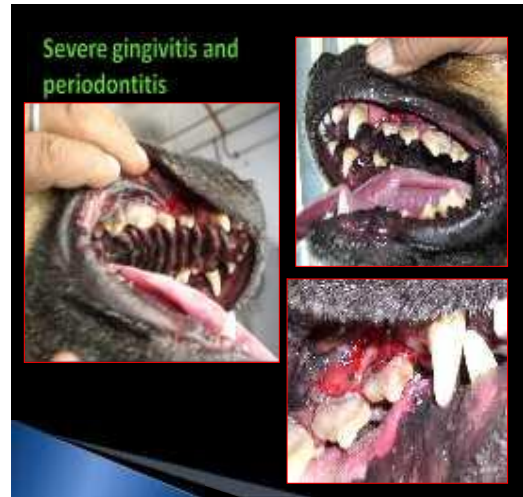

Fig. : 2

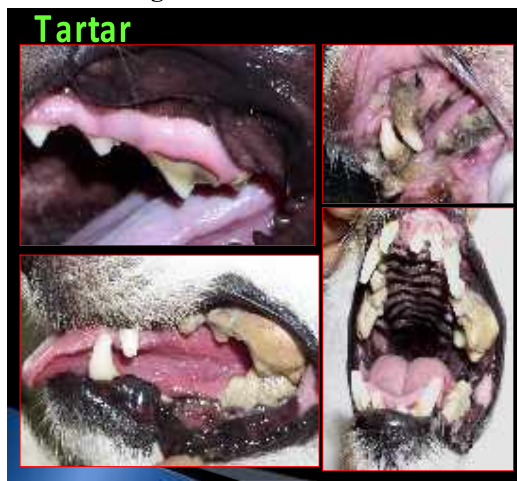

Fig. : 3

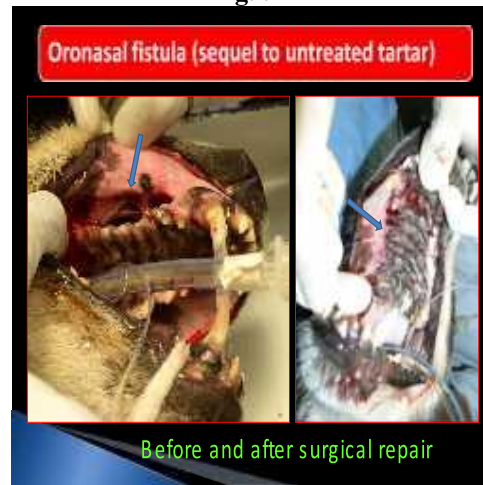

Fig. : 4

pain, profuse salivation, bleeding gums and intolerable halitosis, completely anorexic; severe dental tartar is present on teeth and characteristically mobility of teeth is seen in this condition. *Tooth mobility is graded according to their direction:*

Grade 1 (buccal and lingual), Grade 2 (lateral and medial), Grade 3 (Vertical with lateral and medial).

If any two of this mobility present than tooth extraction is indicated.

Diagnosis

(1) Imaging: As much as, 60% of disease is hidden below the gum line. Severe periodontal disease radiographically appears as loss of bone support around one or more roots.

(2) Periodontal probing: Periodontal depths are measured from the base of the pocket to the

margin of the free gingiva. Probing depths greater than 2 mm in the dog are abnormal.

Treatment

The treatment of periodontal disease is divided into two main sub groups.

(a) Medicinal therapy (b). Surgical therapy.

(a) Medicinal Treatment- For mild to moderate grade of periodontitis.

(i) Tooth brushing with chlorhexidine solution locally.

(ii). Tooth brushing with chlorhexidine + metronidazole gel locally.

(iii) Antibiotics like Ciprofloxacin, Gentamycin, Amoxycillin-Cloxacillin, Doxycycline and metronidazole preparations are administered. orally or I/M to check secondary bacterial infection.

(b) Surgical treatment-For moderate, severe and advanced grade of periodontitis.

Periodontal surgeries are indicated when pocket depth is 5mm or greater and bleeding on probe does not resolve after thorough cleaning.

An ideal method, which allows exposure of the root surface, preserves the attached gingiva, and allows the gingiva to be resutured in a fashion to eliminate the periodontal pocket and promote reattachment to the root surface is chosen.

(A) **DENTAL PROPHYLAXIS:** A dental prophylaxis (cleaning) is performed not only to clean the teeth, but also to evaluate the oral cavity for any other problems that might be present. The dental cleaning must be performed in a methodical manner. All nine steps are important and interlinked.

1) Oral examination on the unanesthetized animal: Face is examined for swelling and painful area specifically around the eyes. Teeth and gingiva is examined for pathology.

2) Oral examination under general anesthesia: Individual tooth is examined for mobility, fractures, malocclusion, and periodontal disease.

3) Supragingival (above the gum line) plaque and tartar removal using calculus removing forceps, hand instruments, and power scaling equipment.

Scaling of teeth may be done with hand instruments alone (Holmstrom *et al*, 1998).

Ultrasonic Cleaning/scaling: The ultrasonic scaler are used to remove plaque and tartar from the teeth.

4) Subgingival (below the gum line) scaling, root planning, curettage: Curettes are used to remove subgingival deposits. The three parts of this step include:

Root scaling: Removal of plaque and calculus from the root surface. The goal is to disorganize and lavage bacteria living subgingivally. Curettes, or slim ultrasonic tips are used.

Root planning: The smoothing of roughened root surfaces by debriding diseased cementum and removing embedded calculus produces a clean smooth surface free of endotoxin. Root planning is performed with a curette used in overlapping strokes. Crosshatch planning creates a smooth surface while maintaining root anatomy.

Subgingival Curettage is removal of the gingival pocket's diseased soft tissue in inner surface. The rationale for the procedure is to convert chronically inflamed ulcerated lesions in the soft tissue wall of a periodontal pocket, into a clean surgical wound. This promotes

healing and re-adaptation of tissue to the tooth surface.

5) Polishing: Polishing smoothes out the defects and removes plaque missed during previous steps. Pumice or polishing paste is used on a polishing cup for the procedure.

Rocken, *et al*. (1996) concluded that polishing after every scaling might extend the required interval between prophylaxis treatments in dogs.

6) Irrigation: With irrigation, diseased tissue and plaque are removed from the pocket or sulcus. Water spray and/or a 0.1-0.2% Chlorhexidine gluconate solution are commonly used.

7) Post cleaning examination and diagnostics: After cleaning, teeth are examined individually via periodontal probing, for retained calculus.

8) Charting: Record disease present before therapy. Charting must include missing, fractured, and discolored teeth, as well as periodontal pocket depths.

B. GINGIVECTOMY: Gingivectomy is the resection of the excess of hypertrophied gingiva that partially covers the tooth. Gingivectomies should only be used in cases of gingival hyperplasia where there is an overgrowth of tissue. The operation is begun by marking the depth of the pocket on the attached gingiva by applying pressure with a periodontal probe. The resected tissue is removed with tissue nippers and curettes, the area is irrigated, and the roots are cleaned.

C. GINGIVAL FLAP SURGERY: It is the most appropriate procedure to expose the pathology and render care in many types of periodontal disease. There are four commonly used methods in small animal dentistry.

(i) Open Flap Curettage - 360-degree incisions are made internally into the pockets, angling the blade tip toward the tooth; the incision is rarely made past the mucogingival line. A periosteal elevator is used to elevate the flap, exposing the tooth's root surface for cleaning and root planning. Inter dental sutures are placed with 4-0 chronic gut on at atraumatic needle.

(ii) Apical Repositioned Flap: This procedure is used to decrease the height of the pocket in areas of alveolar bone loss.

(iii) Reverse Bevel Flap: Indicated where there are inflamed and necrotic free gingival margins. A portion of the attached gingiva is removed; care must be taken to make sure that

enough attached gingiva remains after the procedure.

(iv) Canine Palatal Flap: It is indicated where there are greater than five millimeter pockets on the palatal or lingual side of the canine teeth. If there is an oronasal fistula, as evidenced by sneezing or nasal discharge, then this procedure is not indicated and extraction followed by single or double layer; flap surgical closure of the defect is indicated.

D. GINGIVOPLASTY: Gingivoplasty reshapes the gingiva. The operation is the same as for gingivectomy except that the intent is to create normal tissue contour rather than to resect soft-tissue pockets. It is useful in treating gingival hyperplasia in which the gingiva needs to be recontoured.

E. GINGIVAL CURETTAGE: It is performed to remove diseased epithelium or soft tissue debris from sulcus.

F. PERIODONTAL SPLINTING: Periodontal splinting is done to stabilize teeth that are loosened by the loss of their bony support by periodontal disease.

G. ORONORAL FISTULAS: Oronasal fistulas are most frequently caused by advanced stage of disease. A single layer flap is recommended for the repair of most fistulas. It is initiated by the removal of the entire epithelial edge of the fistula using a blade remove a thin layer of mucosa around the perimeter of the fistula (Fig. 4).

Divergent incisions are made from the medial and distal aspects of the fistula through the mucogingival line extending into the alveolar mucosa. This flap is then elevated gently. Now this flap is retracted laterally and apically to expose the periosteum of the apical region of the flap. Now the flap is positioned over the fistula to ensure that there is no tension on the flap prior to closure. The flap is then sutured to the palatal and gingival mucosa with simple interrupted pattern using 2-0 non absorbable silk thread on reverse cutting needle.

Endodontal Disease

Disease of the pulp cavity caused due to infection or injury of the pulp causing inflammation and subsequent necrosis. It may result into root abscessation and loss of tooth. The condition may result from fracture or caries that exposes the pulp cavity.

Signs: Pain is exhibited by the animal while eating or drinking followed by inflammation of

gum and abscessation. Pain disappears when pulp gets necrosed.

Diagnosis: Endodontic lesions are usually diagnosed by a combination of visual, tactile, and radiographic signs.

1. Teeth with pinpoint exposures of the pulp require tactile confirmation that exposure of the pulp has occurred.

2. A fine, sharp probe is used to explore the suspected area when the probe is successfully passed into the pulp chamber or canal; a diagnosis of endodontic involvement is made. Radiography is useful in confirming endodontic disease in chronic lesion.

Treatment

The goal of endodontic therapy is to salvage the tooth (West-Hyde and Flod, 1995). When possible the vitality of the tooth should be preserved with a direct pulp cap, indirect pulp cap or pulpotomy procedure. The purpose of conventional endodontics is to seal the nutrient foramen in the root so that no further seepage of necrotic debris or bacteria comes from the root. Endodontics therapy is needed to retain a tooth with a necrotic pulp (Eisner, 1992). The term endodontics refers to treatment inside the tooth. Fracture into the pulp is the most common indication for endodontic therapy in dogs.

Emily (1990) described several conventional and surgical techniques, which are used to treat endodontic diseases. Five basic types of endodontic therapy are-

1. Standard root canal therapy: Fractured (broken) teeth, deep cavities, jaw fractures that damages blood supply to tooth, severely worn teeth are the common indication for this therapy. It is performed mostly for deep caries lesion in People, but mostly for fractured teeth in animals. Any cause of tooth death is an indication for this procedure (Eisner, 1993).

2. Direct pulp capping or vital pulpotomy: Performed in case where the pulp is exposed, but may be still healthy and further maturation of the tooth is desired. It is used in patients under 18 months of age.

3. Surgical root canal therapy: It is done when conventional root canal therapy fails or when the canal is blocked by a pulp stone or other impediment. It requires an incision in the gingival (gum) tissue and removal of some jawbone to expose the tip of the tooth root (apex). The tip is removed, and the canal filled from the bottom.

4. Indirect pulp capping: It is performed when the defect in the tooth get close to the

pulp but not into it (Eisner, 1992). A layer of a medicament called calcium hydroxide is placed over the bottom of the defect. A standard restorative is placed over the lining.

5. Apexification: Performed in a dead, immature (has not closed at the bottom) tooth, which is very valuable. The tooth is cleaned as in the standard root canal therapy. Then the canal is filled with calcium hydroxide to stimulate the tooth to complete the development of the bottom (apex) of the tooth.

Orthodontic Problems

Anodontia and oligodontia: Anodontia is the complete congenital absence of teeth, which involve both the deciduous and permanent dentition. Oligodontia, or partial anodontia, is the congenital absence of one or more teeth. Oligodontia is much more common is permanent dentition than in the deciduous dentition (Harvey, 1985).

Polydodontia: Polydodontia or supernumerary teeth means having extra teeth. These teeth may cause malocclusion and crowding as well as incomplete eruption or impaction of adjacent teeth.

Retained deciduous teeth: A deciduous tooth may persist because of the absence of the corresponding permanent tooth and the resulting incomplete root resorption. Retained deciduous teeth alter the gingival contour, with plaque and debris accumulating between the deciduous and permanent teeth. (Lund *et al.*, 1999).

Embedded and Impacted Teeth: Embedded teeth are individual teeth that are unerupted, usually because of lack of eruptive force. An impacted tooth is prevented from eruped by some mechanical barrier in the eruption path.

Occlusion and malocclusion: The normal occlusion pattern is classified as an incisor scissor bite. A scissor bite occurs when the mandibular incisors are behind and resting on the cingulum of maxillary incisors. The mandibular canine teeth interlock rostral with the maxillary canines and equidistant between the canines and the lateral incisors. Any deviation from normal occlusion is classified as some degree of malocclusion.

Restorative Dentistry

Restorative dentistry is the branch of dentistry that deals with the replacement of tooth structure for both esthetics and function.

A. CAVITY RESTORATION: By using high-speed dental bur (drill) all the diseased tooth

structure is removed. Then, the cavity is prepared to accept the restoration (filling). Depending on the filling material used, an undercut is usually made to increase retention of the restorative. Next, a filling is placed in the defect. The filling is allowed to harden (cure).

Categories of Restorative Material:

There are only a few simple classes of materials used for direct placement restorations. The "gold standard" with the longest clinical success is amalgam. Newer materials are composite, glass ionomer, or some mixture of composite and glass ionomer. (Gorgul, *et al.*, 2001) stated that the both amalgam and composite material can be used as restorative material.

Glass Ionomers - GI's are best used over eugenol-containing materials (e.g. endodontic access preparations) and in class V lesions where minimal tooth removal and cavity preparation is required and local release of fluoride may be helpful.

Composite Resins - composites are best suited for almost all surface restorations that require high polishability for minimal plaque accumulation, resistance to wear, and fracture toughness. For caries restoration on occlusal surfaces, a posterior resin can be placed. Composites require a bonding agent.

Alloys - Amalgam is still a good choice for occlusal lesions on posterior teeth. A bonding agent should be placed under the amalgam to seal the dentin from micro leakage and corrosion by-products. Ross (1977) stated that success of restoration will depend upon the depth of restoration, the cleanliness of the canal, the compactness of the filling and the lack of microleakage of the restoration.

Bonding Agents: Bonding to enamel using acid etch techniques to develop a micro - mechanical bond is relatively routine. The dentin bond is achieved with most modern materials through the use of hydrophilic / resins that form resin tags into open dentinal tubules and also form a layer of hybridization incorporating dentinal collagen with the resin.

B. CROWN THERAPY: Crown therapy is an option in broken or diseased teeth. Crowns are predominately fabricated to increase the strength and size of a fractured tooth. Crown therapy in dogs can be an effective tool for maintaining the tooth, as well as increasing the size of the remaining tooth.

C. ENAMEL YPOPLASIA RESTORATION: There are three basic goals to the treatment of enamel hypoplasia (actually enamel hypocalcificatin). The first is to remove the dentinal sensitivity produced when the enamel is lost from the tooth surface. The second is to improve esthetics (or looks) of the tooth. Finally, depending on the severity and location of the defect, additional strength may be desired to decrease wear and the possibility of fracture.

Oral Surgery

1.Dental extractions (exodontia): Extraction of diseased and malformed teeth is an essential part of veterinary oral surgery. Indications for extraction include: End-stage, periodontal disease, end-stage endodontic disease, pulp exposure when endodontic treatment is not elected, malocclusions, crowding, retained deciduous teeth, trauma, plaque-intolerant animals, and disarming.

General Comments on Extraction Techniques :Extracting teeth is made less difficult when the following principles are understood,

- Pain management must be addressed. Various pain management techniques must be used including medical management (pre-surgical and post-surgical medications), regional nerve blocks, and local nerve blocks.
- The top (coronal) 1/3 of the alveolar bone surrounding the tooth has 2/3rds of the holding power.
- Periodontal fibers are not designed to withstand slow, continuous torque.
- Multi-rooted teeth are transformed into single-rooted teeth. Gingival preservation is paramount.
- Complete extraction of root confirmed by radiograph. Closure of alveolus to maintain blood clot.

Surgical Extraction: Surgical extraction is performed on non-mobile teeth with normal or near normal attachment levels. Each step is equally important and short cuts generally end up as surgical misadventures.

Periodontal disease is the most common of all small animal maladies. The literature reveals that 80% of the dogs over three year of age have same degree of periodontal disease. The dental problems are more common than the skin and gastrointestinal problems but because of mild symptoms, problems remain unnoticed to pet owners & veterinarians. Due to poor

dental care & hygiene the affections terminate to major disease in old age dog.

Due to lack of technical skills and sophisticated instrumentation canine dentistry is yet considered as a foreign concept for most of the veterinary practitioners. Desire is the key to unlock the mysteries of dentistry. Better patient care should be the reason enough for any practitioner to want to improve dental skills and everything paying attention to dental abnormalities can translate in better patient care and Client appreciation. Apart from vets, pet owners awareness needs to be improve for getting the success in the field of canine dentistry.

With the advancement in the knowledge and equipmentation in canine surgical field, the day is not far when better dental practices will also include in routine veterinary surgery.

References

- Court, L.A., Gimpel, R.J. and Rivera, L.S. 1993. Dental abnormalities in dogs. *Advances-en-CienciasVet.*8: 69-71 (CAB Abstracts 1993-1994).
- Eisner, E.R. (1992). Three endodontic procedures Pulp capping. Pulpotomy and apexification. *Vet Med* 87(5):450-458.
- Eisner, E.R. (1993). Standard root canal therapy preparing and filling the root canal. *Vet Med* 88 (3):252-262.
- Emily, P. (1990). Problems associated with the diagnosis and treatment of endodontic disease. *Problems in Veterinary medicine.* 2 (1): 152 -182.
- Gorgul, O. S.; Kaya, M.; Manik, S.; Topai, A; Altikardesler, A (2001). Restorative and endodontic surgery in dogs. *Veterinari Ce"ahi Dergisi.* 7 (112) : 48-59.
- Grove, T.K (1982). Periodontal disease. *Comp Cont EdNe Proct VeL* 4: 564.
- Harvey, C.E : (1985). Veterinary Dentistry. In: Text book of small animal surgery. Ed. Slatter D.2nd Edn, W.B. Saunders Company, Philadelphia pp. 2310.
- Harvey, C.E. and Emily, P.P.1993. Veterinary Dentistry. I edn. W.B. Saunders. Philadelphia, pp. 891-944.
- Holmstrom, S. E. (1998). Canine dentistry. *Veterinary Clinics of North America. Small Animal Practice:* 28 (5): 1049-1324.
- Lund, E.M., Armstrong, J.P. and Kirk, C.A. 1999. Health status and population characteristics of dogs and cats examined at private veterinary

- practices in the United States. *J.American Vet. Med.Assoc* 214:1336-1341.
- Merillat, L.A;(1908) Animal dentistry and disease of the mouth. In: *Text hook of small animal surgery*. Ed. Slatter D. 2nd Edn., W.B. Sounder Company, Philadelphia. pp.2311.
- RockeD, F. E.; Pollmeier, S.; Fabrenkrug, P; Trautvetter, E. (1996). Efficacy of polishing after calculus removal and its influence on new formation of plaque and calculus in dogs. *Praktische Tierarzt* 77 (8) : 701-711.
- Vasseur, P.B. et al. (1981). The colome and distribution of surgical cases in 78 small animal practices in California 1. *AmAnim Hosp Associ. 17*: 161.
- West-Hyde, L. ; Plod, M. (1995). Dentistry. In Ettinger 8J (00): *Textbook of Veterinary Internal Medicine*. 4th Edn., Philadelphia, WB Saunders. pp 1097-1123.

#####